The Institute of Cancer Research

Progress in quantitative elastography for cancer medicine

Jeff Bamber

Joint Department of Physics, Institute of Cancer Research and Royal Marsden Hospital, Sutton, Surrey, UK

ICR The Institute of Cancer Research 1909 2009

Working in partnership with

EPSRC Engineering and Physical Sciences Research Council

CANCER RESEARCH UK

NHS National Institute for Health Research

NSF and NIH

Acknowledgements

- Material used from students and staff within the team at the Institute of Cancer Research, most recently:
  - Leo Garcia, Christopher Uff, Remo Crescenti, Gearoid Berry, Louise Coutts
  - Naomi Miller, Nigel Bush, Jeremie Fromageau, David MelodeLima, Lijun Xu
- Collaborators:
  - Boston Uni: Paul Barbone, Assad Oberai, and students
  - Rensselaer Poly: Assad Oberai, and students
  - Royal Free Hos: Aabir Chakraborty and Neil Dorward
  - Cambridge Uni: Andrew Gee, Graham Treece et al
  - Royal United Hos: Francis Duck et al.
  - Zonare: Anming Cai, Glenn McLaaughlin, Larry Mo
- Apologies for any omissions!

Palpation, an ancient diagnostic technique

- Hippocrates: for battle injuries, if the bone is not visible palpate to locate weapon mark, determine whether bone is denuded of flesh and, for head injuries, whether the cranium underneath is strong or weak.
- Egypt ~1900BC: palpation mentioned in the Edwin Smith Papyrus.
- Still valuable, both by doctors and in “self examination” techniques
- Limited to a few accessible tissues and organs
- Interpretation of information is highly subjective

Ultrasound elastography

- Mechanical "palpation" images that are related to a broad range of tissue viscoelastic parameters, obtained by processing time-varying echo data to extract the spatial and temporal variation of a stress-induced tissue displacement or strain.
- Principle of (most current) Elastography: Consider only the stiffness according to Hook's law, and use ultrasound to image the tissue strain that results from an externally applied stress.

  Ignore what happens to the internal stress.
- Related to work that dates back to the 1970s in France and Belgium.

Methods for ultrasound elastography

- Method of applying stress:
  - static / dynamic source, step / vibrational / impulse, transducer displacement / separate source / acoustic radiation force, shear / compressional source, applied displacement / force, constrained mechanical / hand-induced motion, large displacement / small / incremental
  - surface loading / deep loading (radiation force)
- Signal measurement:
  - displacement / strain / other
  - Doppler / speckle decorrelation / speckle tracking / RF tracking / texture change / frequency shifting (plus hybrids, spatial / frequency domain implementation of tracking)
  - Other variables: tracking interpolation techniques, 1D / 2D / 3D data, displacement vector components, steered beams, decorrelation minimisation or correction methods, strain estimators

Bamber JC et al (2002) Progress in freehand elastography of the breast. IEICE Trans on Information and Systems; 85-D(1):5-14.

Strain Imaging

- Image a region of interest by conventional ultrasound => "*undeformed image*"
- Gently press on the skin surface and image again => "*deformed image*"
- Compare structures in the two (RF) images => *displacement image*
- Calculate the difference in displacement from one axial position to the next => axial *strain image*, or "*elastogram*" (Ophir et al, 1991)

Ultrasound echo tracking

Before compression

After compression

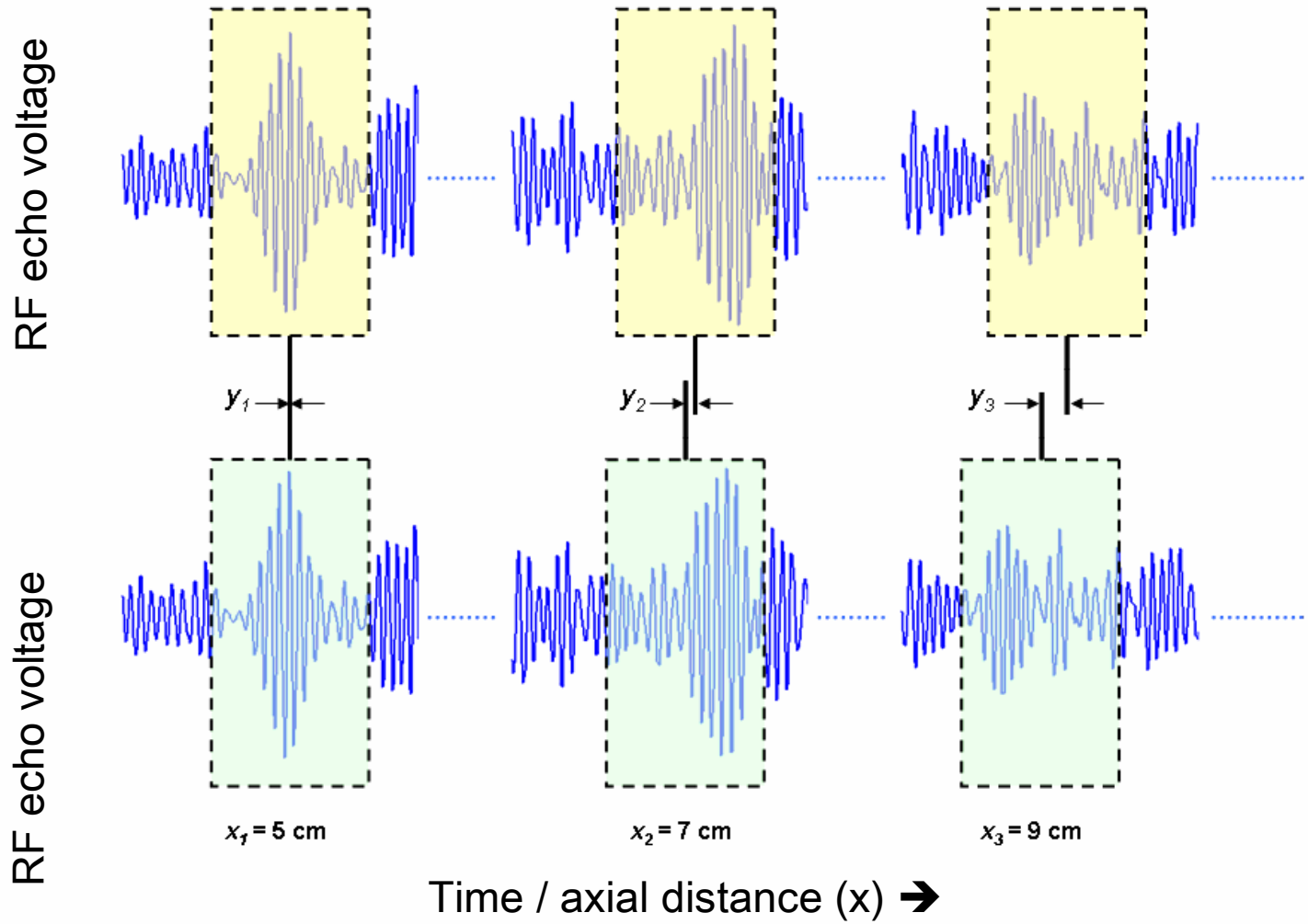

Adapted from J Civale, PhD thesis, University of London, 2007

Real-time freehand strain imaging

- Systems from various companies:
  - Hitachi, Siemens, Medison, Ultrasonix, Toshiba, Zonare
- Various real-time algorithms:
  - Zero phase root seeking
  - Combined RF + envelope autocorrelation
  - 2-D correlation tracking
  - Doppler (TD strain rate imaging)
- Promising results from trials in test clinics around the world

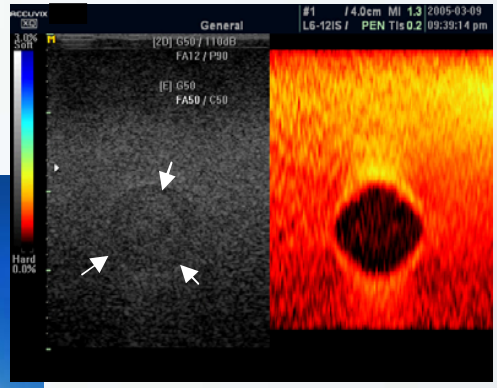

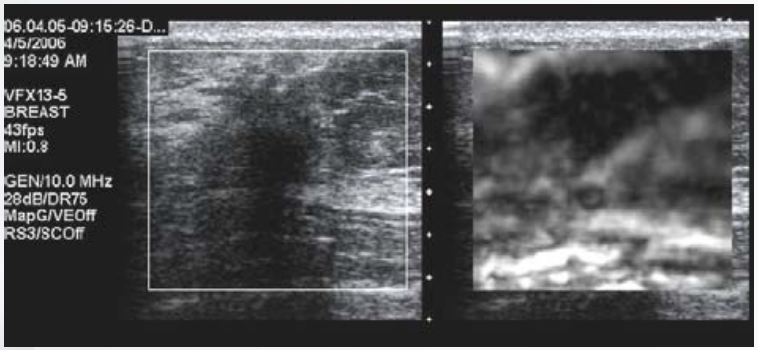

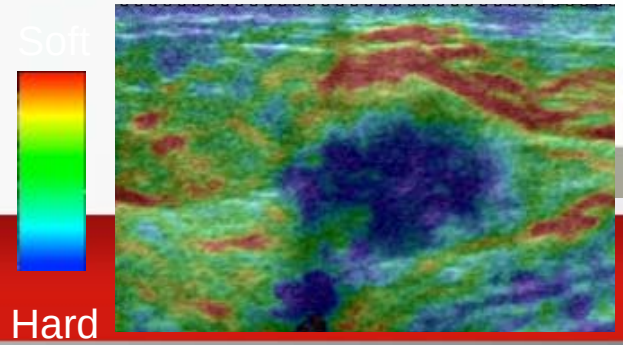

Typical elastographic (left) and echographic (right) appearance of a malignant breast tumour

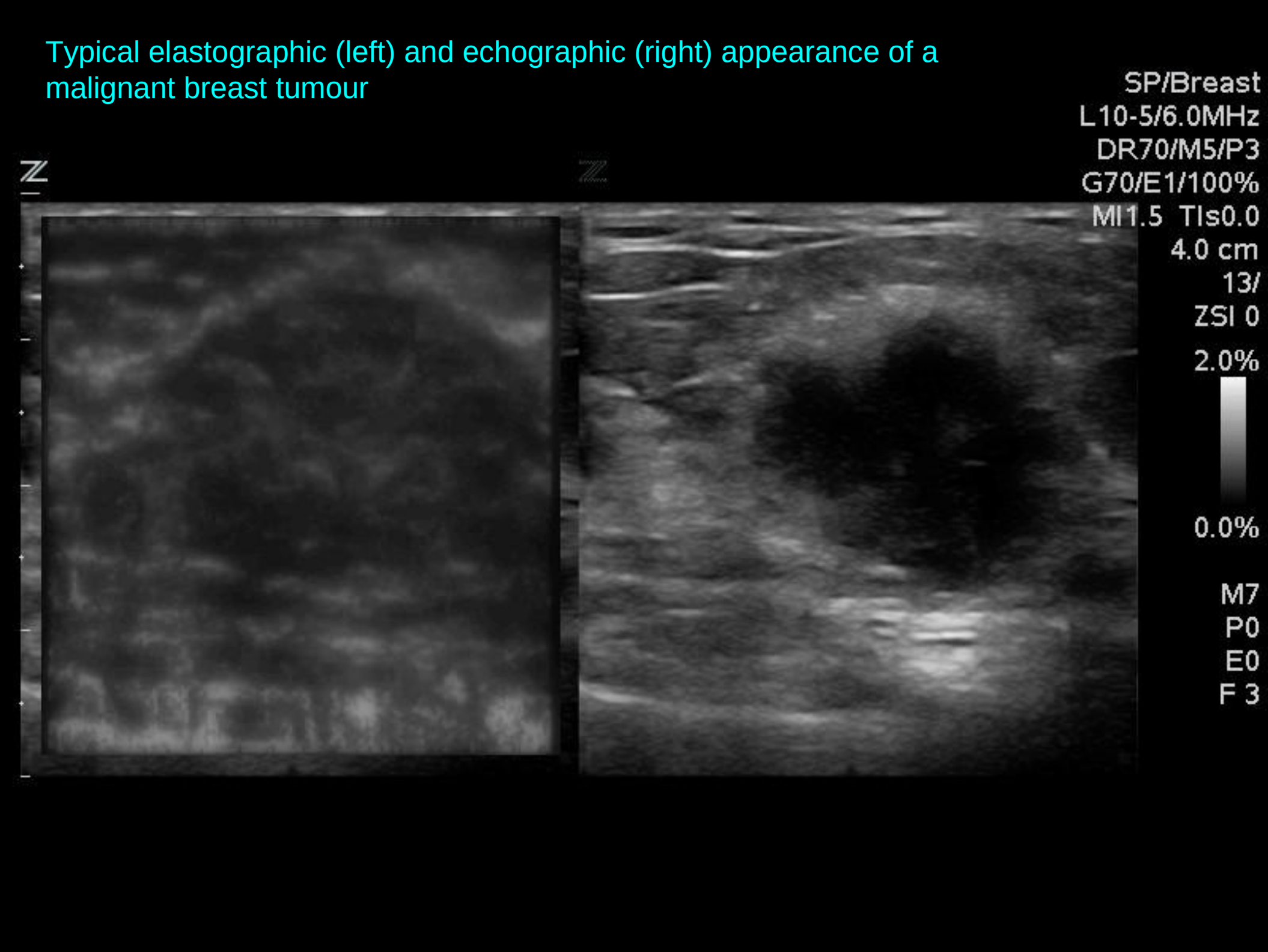

Methods for assessing tissue elasticity

- Manual palpation
- Visual relative motion assessment during a dynamic ultrasound examination
- Measurement/imaging of displacement, strain, etc.
- Quantitative reconstruction of mechanical characteristics

Increasing system complexity but decreasing complexity of image interpretation.

Freehand strain images (elastograms) of a stiff spherical inclusion

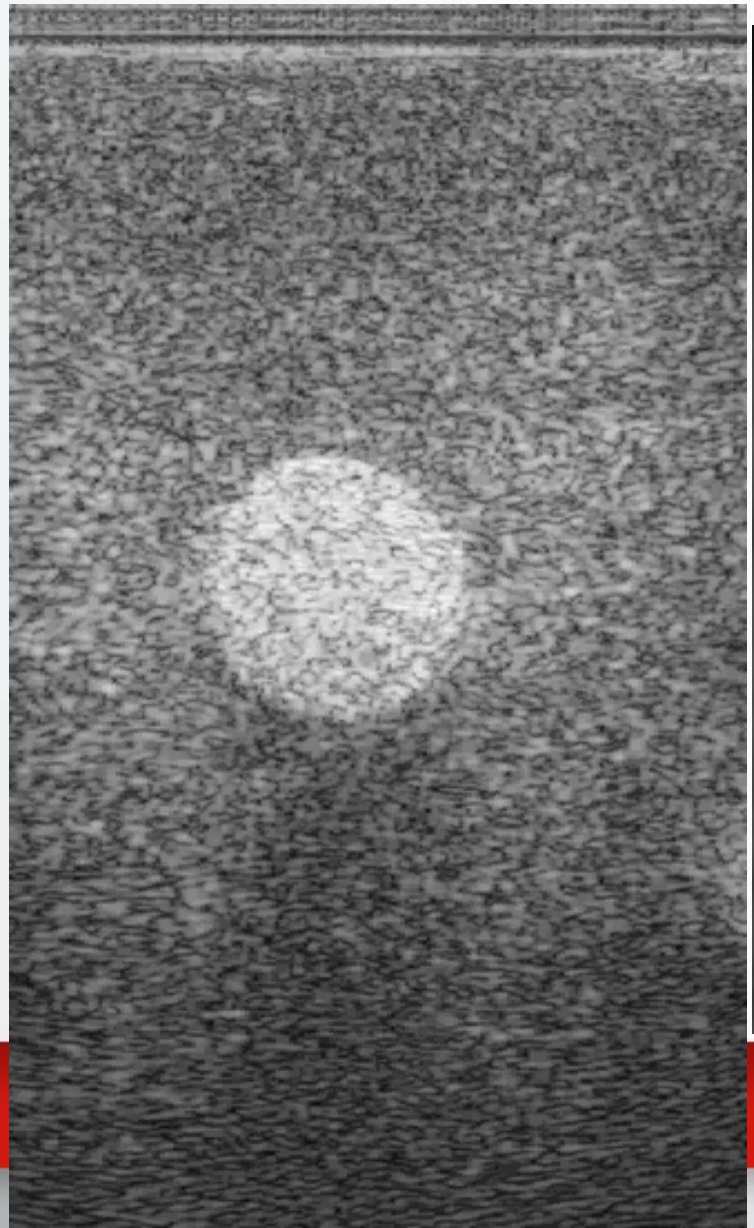

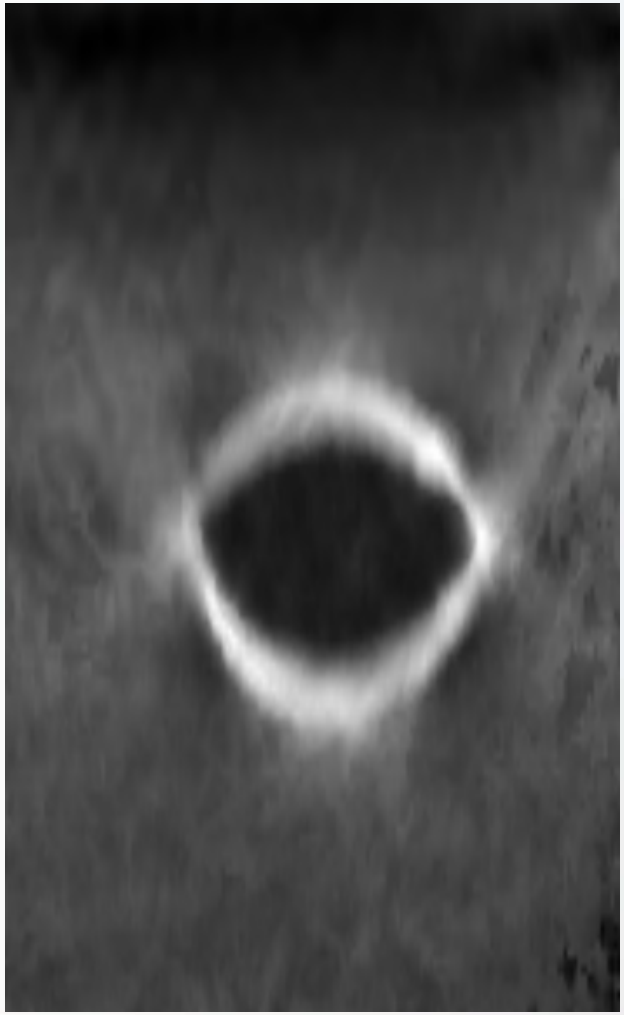

Contrast and diameter required for visual detection of elastic lesions

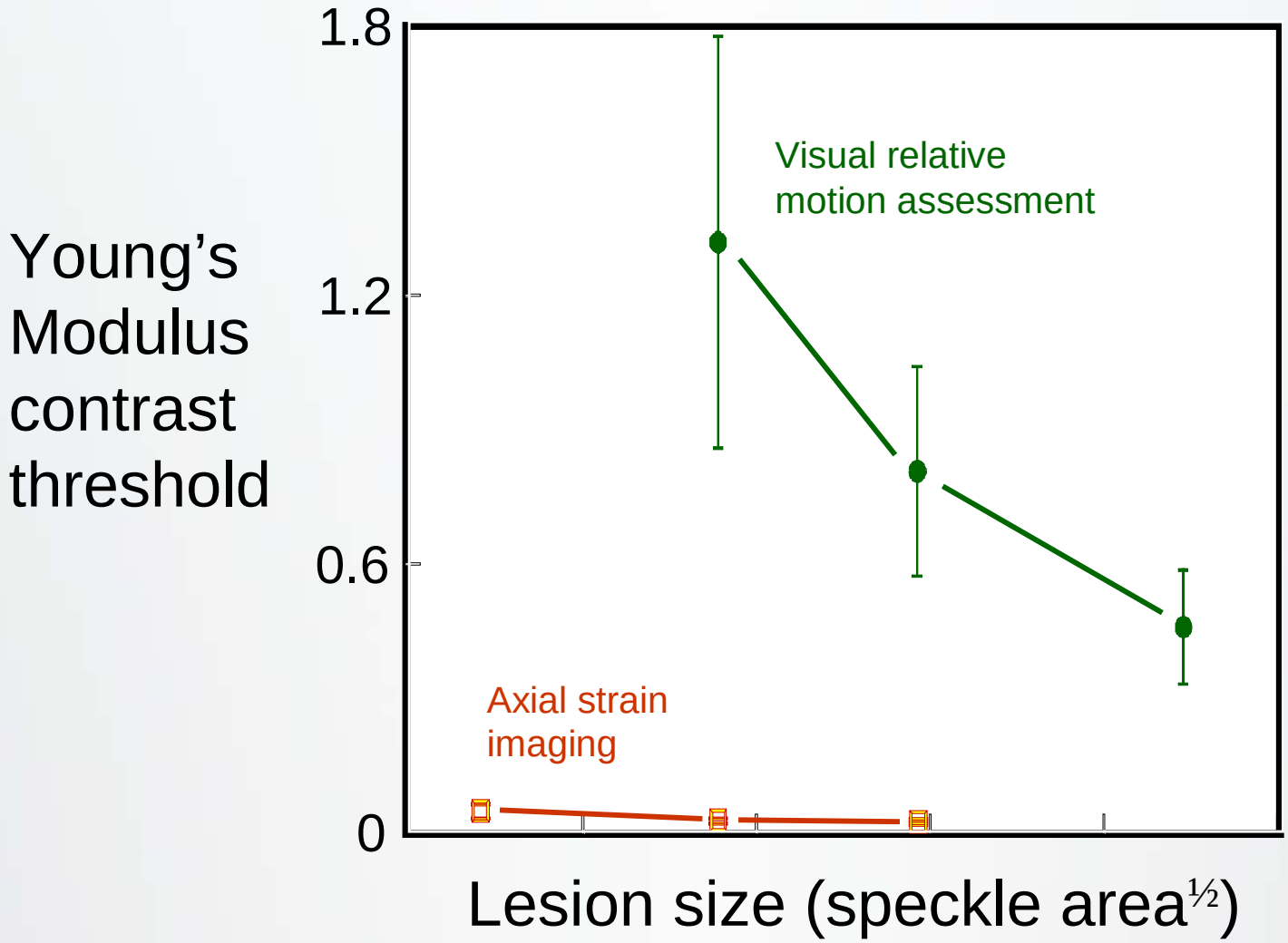

Miller NR, Bamber JC (2000) Phys Med Biol; 45:2057-2079

Quantitative elastography

- Absolute values of mechanical characteristics
  - Improved differential diagnosis, i.e. tissue characterisation (where have we heard this before?).
  - Ability to pool data in multi-centre studies.
  - Early assessment of onset of various conditions, monitoring of response to treatment.
  - Potential for thermal dosimetry.
- Reliable relative values may be sufficient for some applications, where there is a calibration control.
- “Cleaning up” elastograms: a by-product of having to account for boundary conditions.
- Improve contrast resolution by separating variables.

Quantitative elastography: potential / challenges

- Quantity imaged / measured:
  - Young's modulus ← **Most work to date**
  - Non-linearity
  - Viscosity
  - Hysteresis
  - Anisotropy
  - Poisson's ratio
  - Porosity and permeability
  - Mechanical discontinuities / low friction boundaries
- Current approach: to study, experimentally and theoretically, the relative importance of a number of mechanical characteristics in a variety of situations.

Use of a calibrated elastic stand-off

- *Interests*:
  - Potential for an objective non-invasive imaging method for assessing and monitoring the severity and treatment of breast fibrosis?
  - Quantitative diffuse tissue stiffness measurements using freehand ultrasound strain imaging?

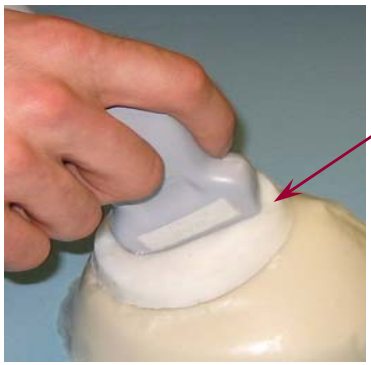

Compliant, gelatine or PVA gel pad of measured elastic modulus, loaded with acoustic scatterers ➔ measure of applied stress profile at tissue surface.

First-order correction to strain image data for non-uniform stress fields, by a column-wise reference to the strain in the overlying region of the standoff, defined with the aid of registered B-mode images.

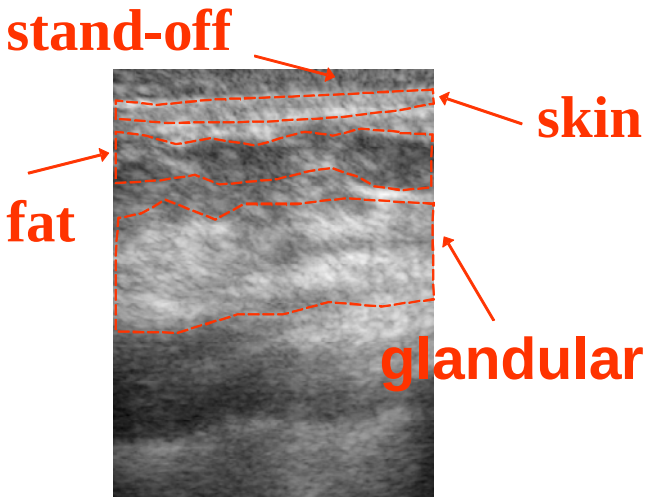

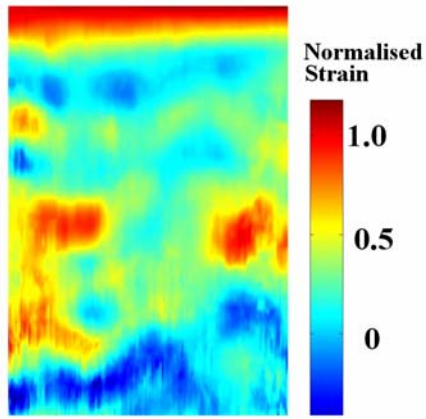

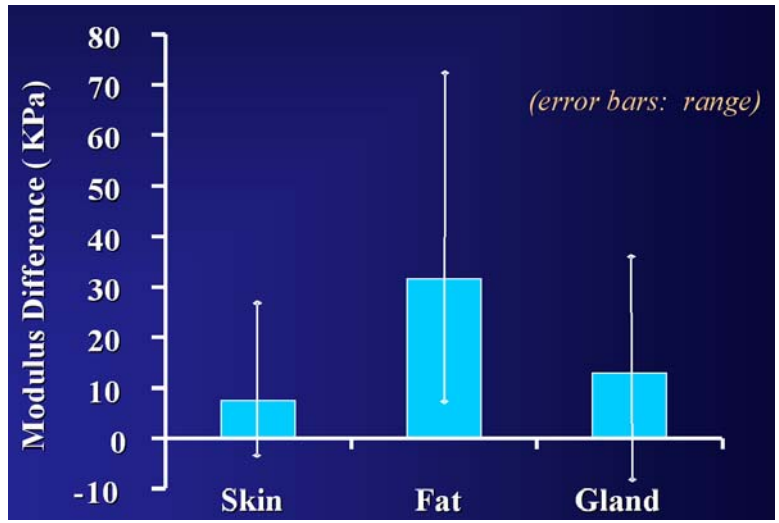

Bush NL et al (2005) Proc. 4th Int Conf on the Ultrasonic Measurement and Imaging of Tissue Elasticity, Oct.16-19, Austin, Texas.

Trans-abdominal strain ratios for liver fibrosis

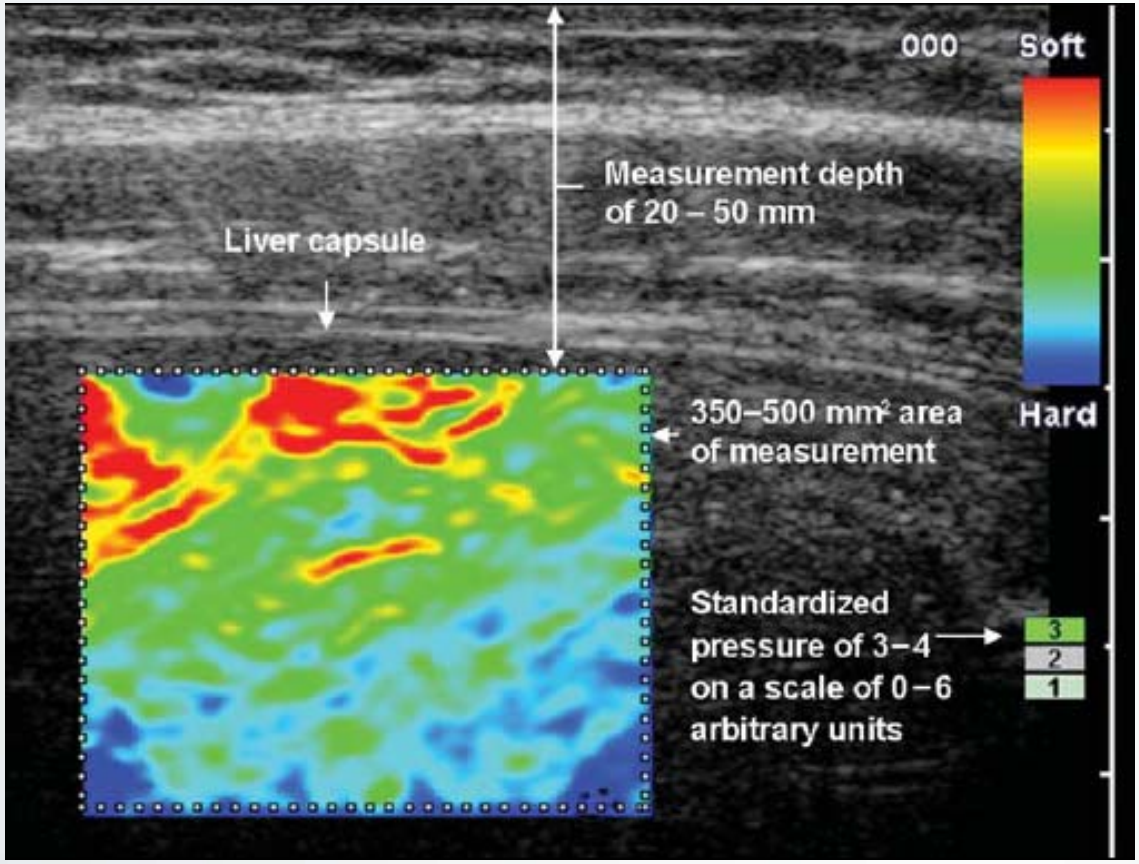

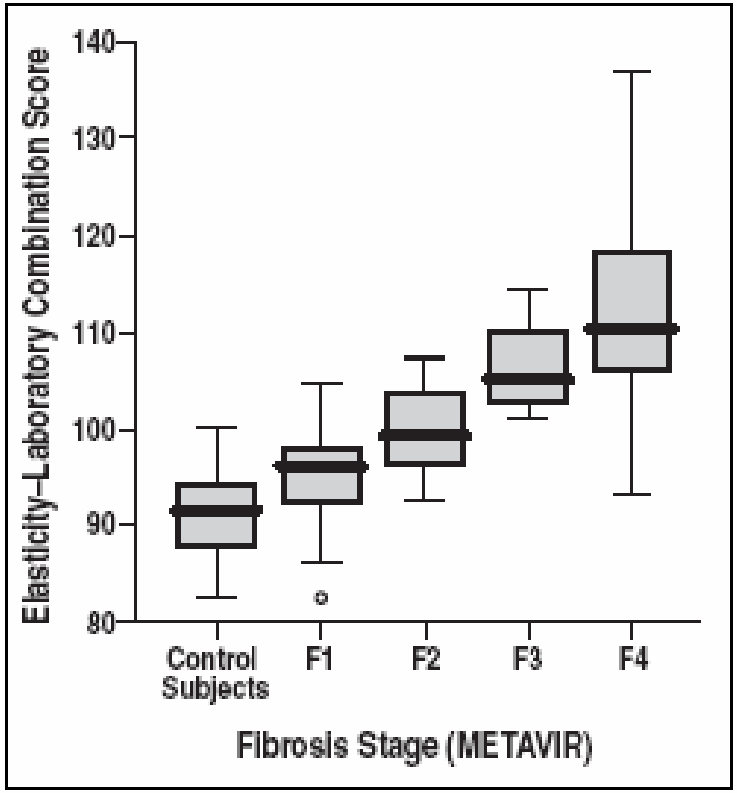

Sufficient standardisation possible for useful combination with aspartate transaminase–to–platelet ratio index

Source: Friedrich-Rust M et al. AJR, 188:758, 2008

Quantitative stiffness imaging

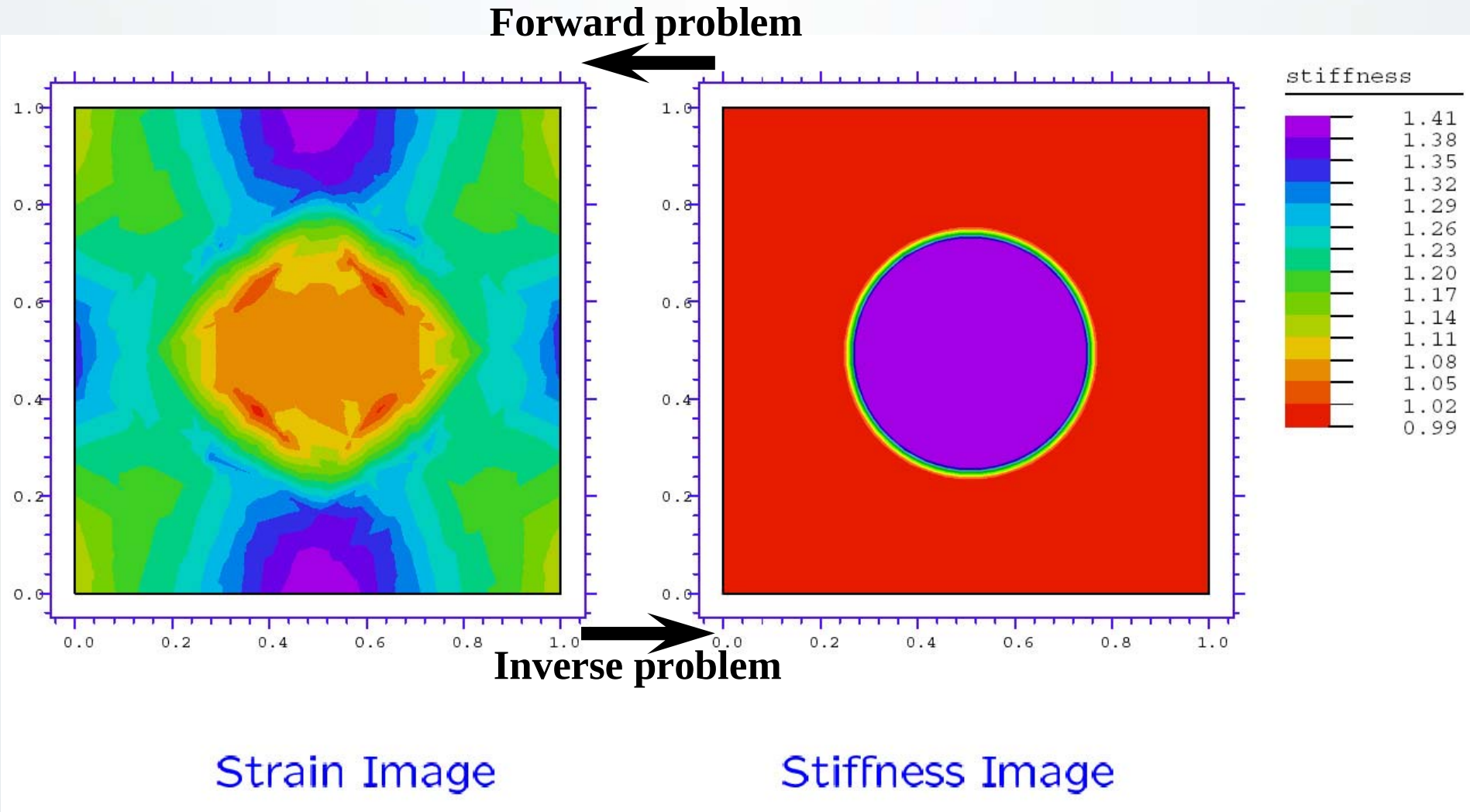

Barbone PE, Bamber JC (2002) Phys Med Biol; 47:2147-2164

Simple iterative reconstruction

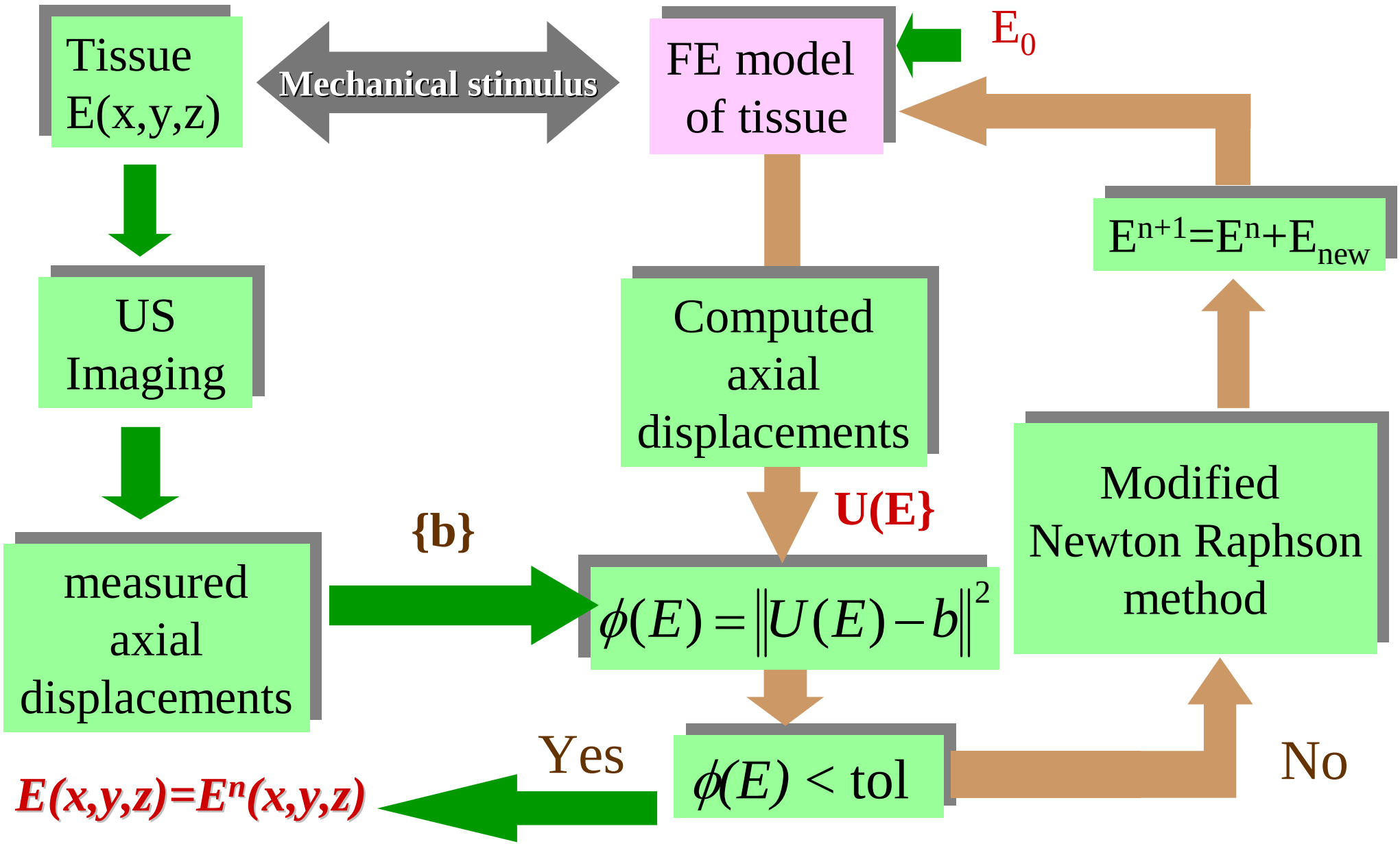

Doyley MM, Meaney PM, Bamber JC (2000) Phys Med Biol; 45:1521-1540

Single lesion reconstruction

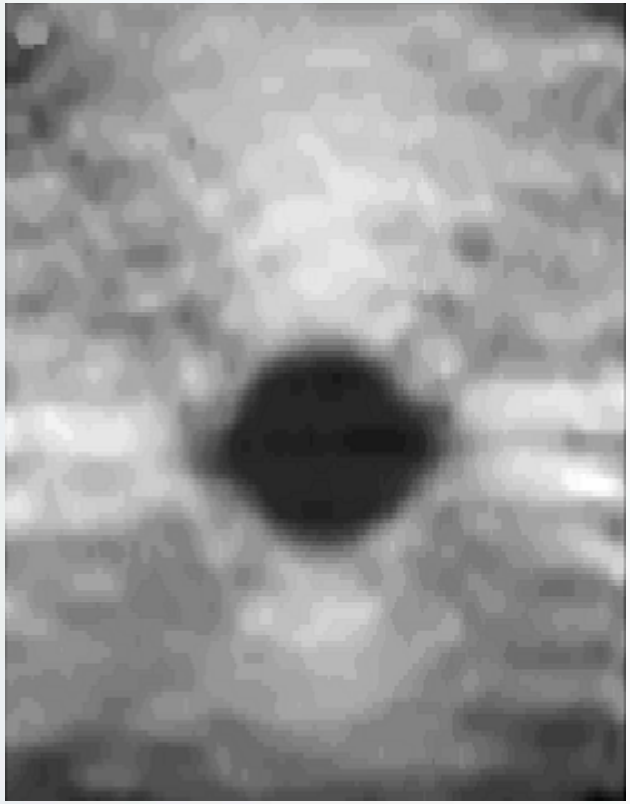

Strain image



Relative Young's modulus image

Doyley MM, Meaney PM, Bamber JC (2000) Phys Med Biol; 45:1521-1540

Relative reconstruction of phantom containing 3 lesions



Sonogram

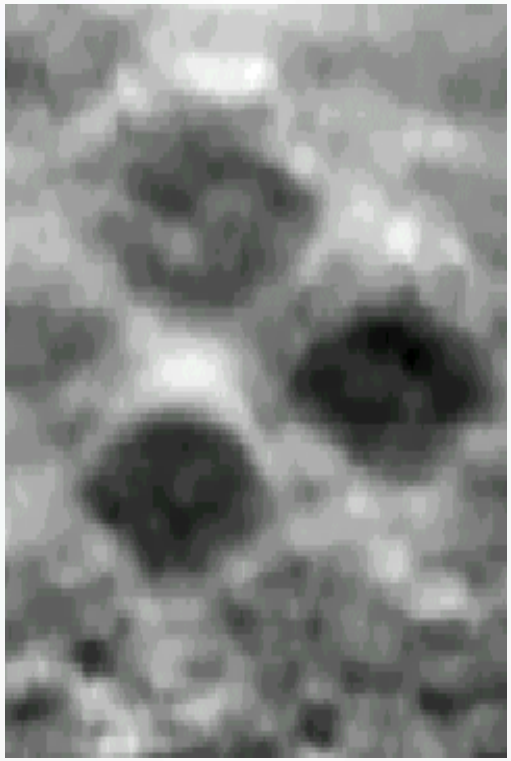

Strain image



Relative Young's modulus image

Imaging ionising radiation dose

- The need: to measure absorbed dose distributions in 3D
  - verify complex 3D treatment plans (conformal radiotherapy)
  - study effects of motion, and of motion correction strategies

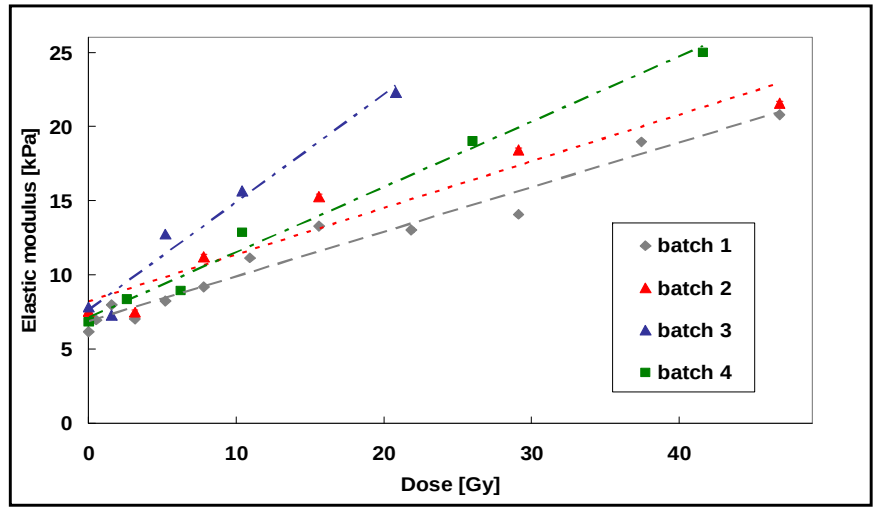

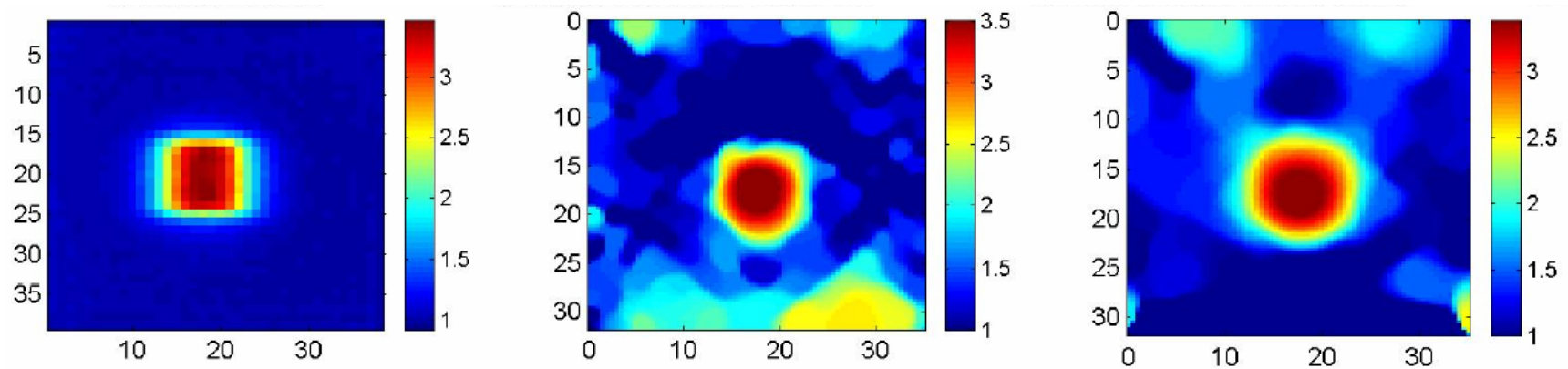

Relative dose: MRI EI (slippery top and bottom) EI (slippery top and sticky bottom)

Crescenti RA et al (2007) pp. 2025-2027 IEEE Ultrasonics Symposium, ISBN: 1-4244-1384-4, IEEE, Piscataway, NJ

Other approaches to Young’s/shear modulus determination

MR elastography

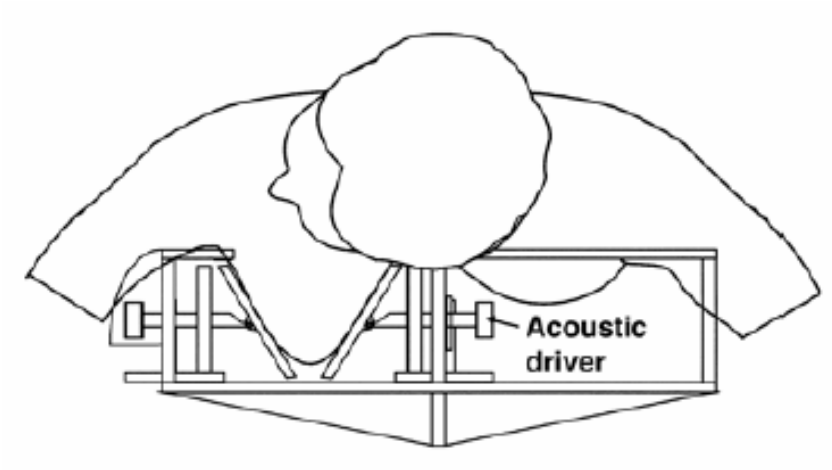

- Fully 3D
- Quantitative
- Registered with MR images
- Vibration frequency variable (study viscous effects)
- Directionally sensitive (study anisotropy)
- Many research groups
- Commercial versions
- All the practical cost, availability, slow acquisition, and convenience disadvantages of MR

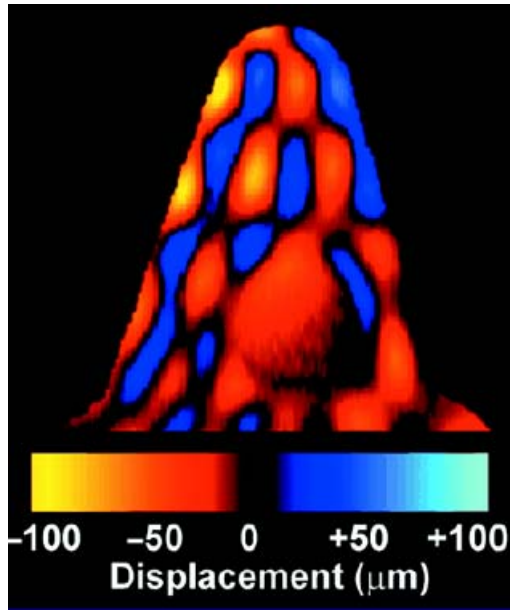

Image of breast phantom showing standing wave pattern for 100 KHz vibrations

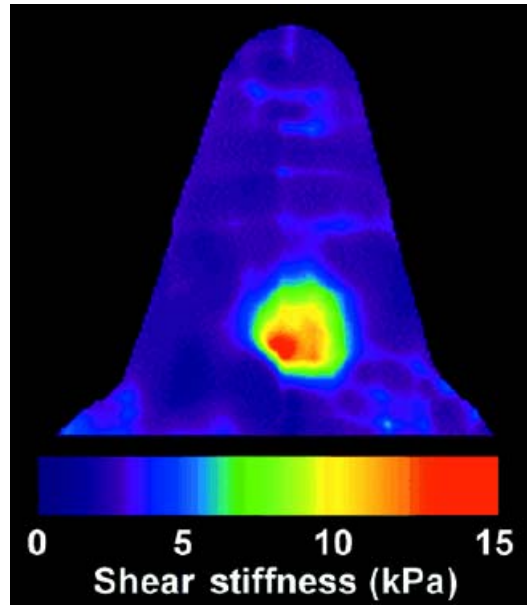

Image reconstruction from data on the left, showing shear stiffness in kPa.

$$c_s = \sqrt{\frac{E}{3\rho}}$$

Dates from Muthupillai R et al. Science 269 (5232):1854-1857, 1995

Ultrasound to measure shear wave speed

CW shear excitation, either with 2 interfering sources to generate “crawling waves”, or with a single source and an oscillating ultrasound probe (as below) to stroboscopically sample the shear propagation

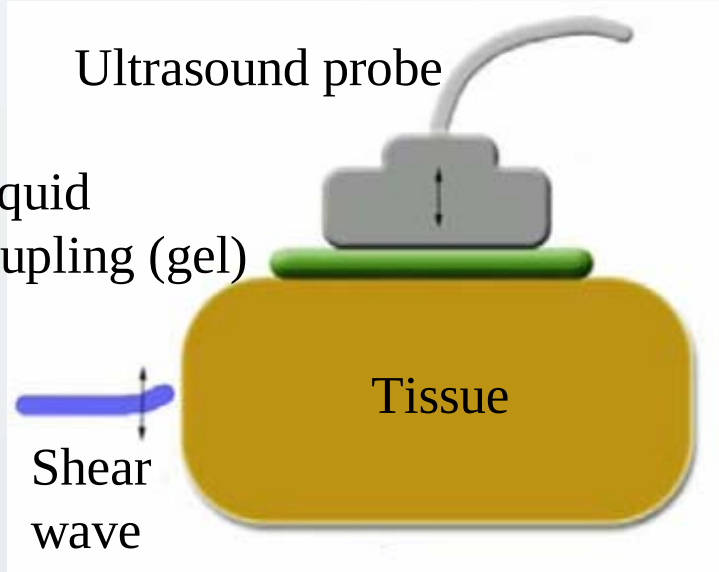

$$c_s = \sqrt{\frac{E}{3\rho}}$$

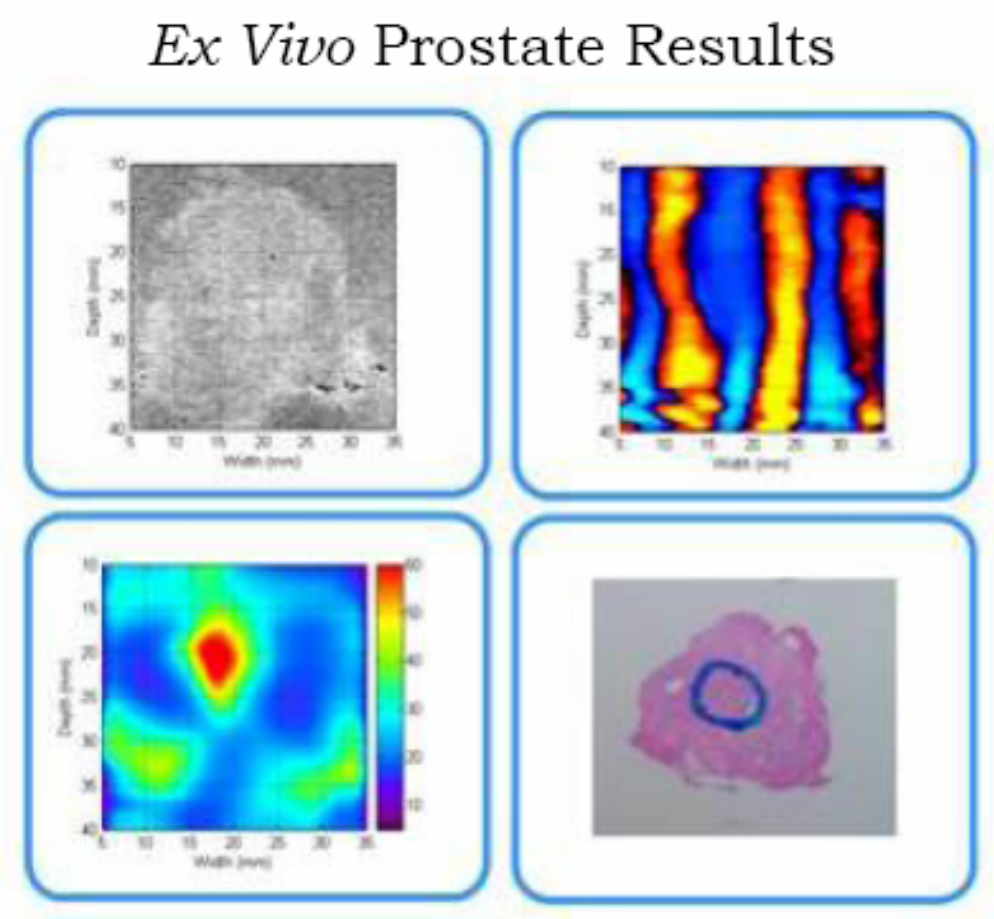

K. Parker et al. University of Rochester

Modulus imaging by travelling shear wave inversion – tissue surface impulse excitation

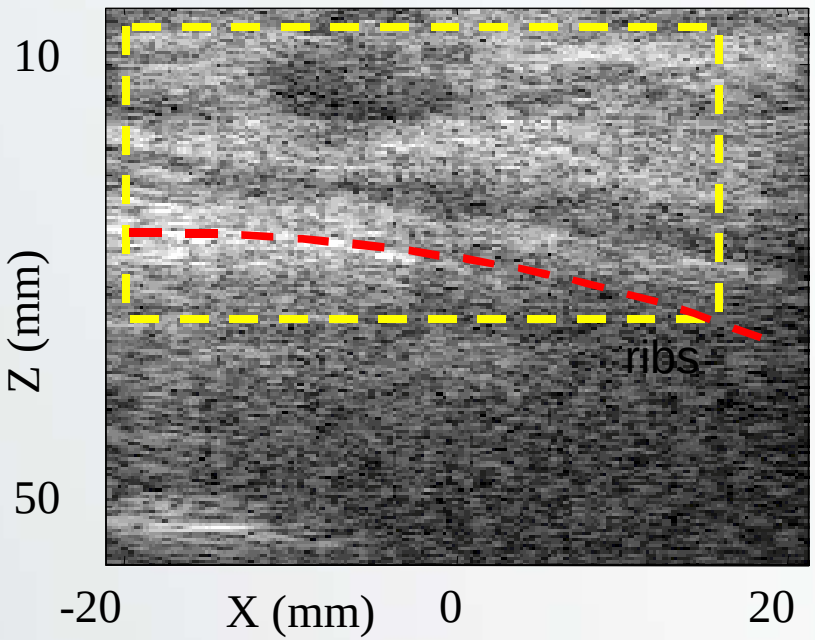

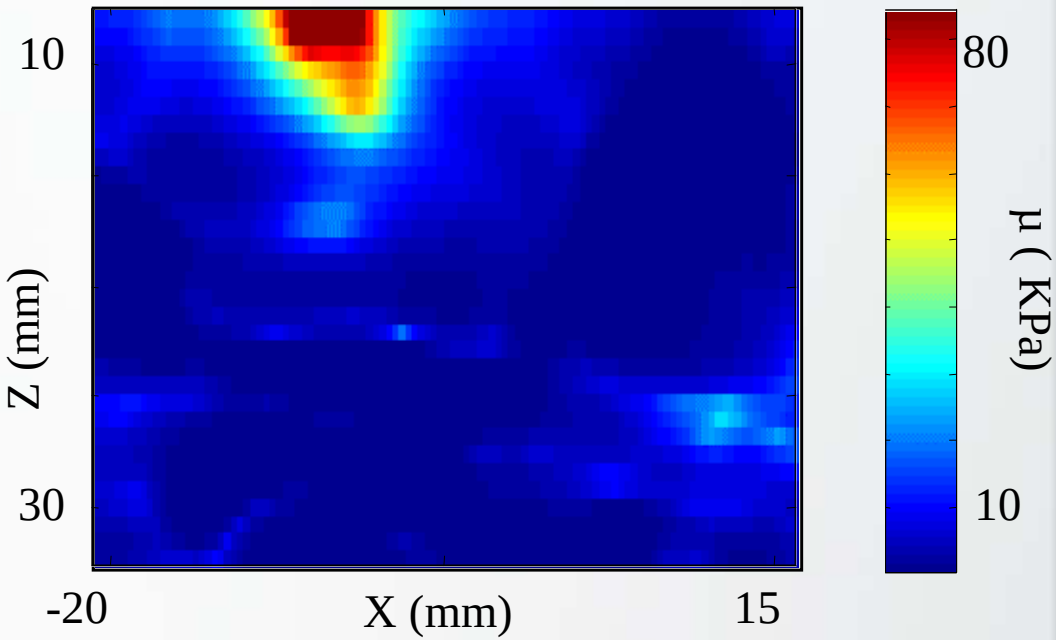

L. Sandrin, S. Catheline, M. Tanter, X. Hennequin and M. Fink. "Time-resolved pulsed elastography with **ultra fast imaging**", Ultrasonic Imaging Vol. 21, pp.259-272, December 1999.

Localised transient displacement from a focused radiation force impulse

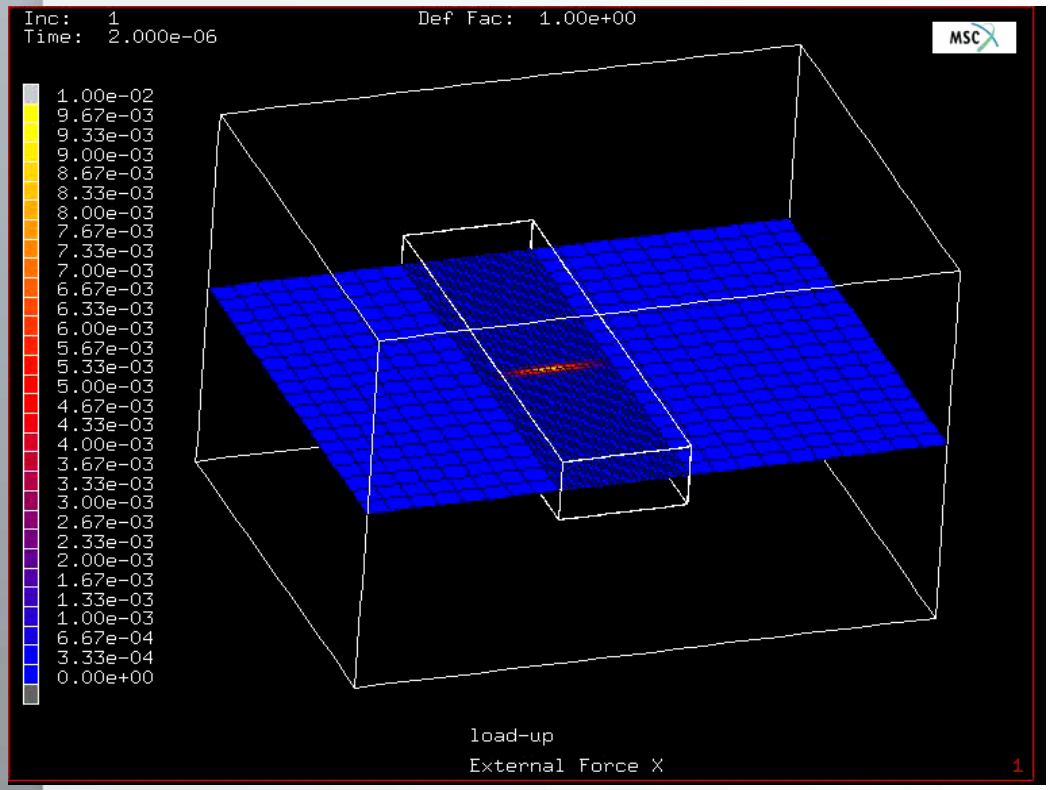

Force applied for duration of 1 ms

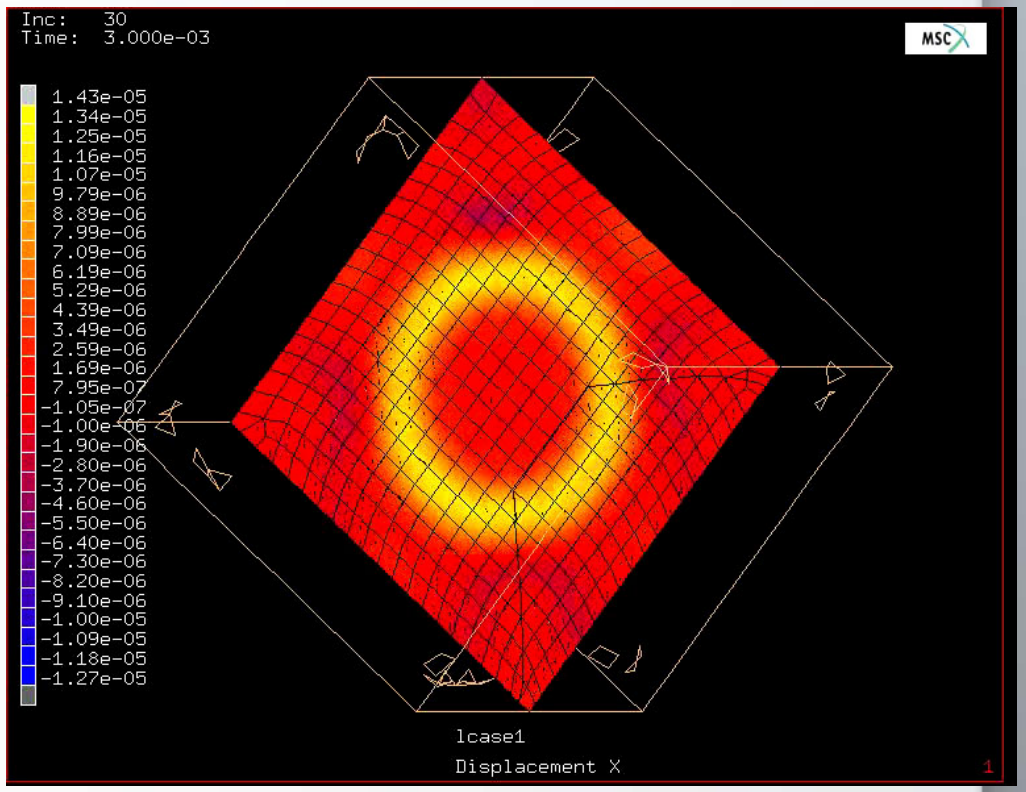

Displacement distribution after 3 ms

System from “Supersonic Imagine”

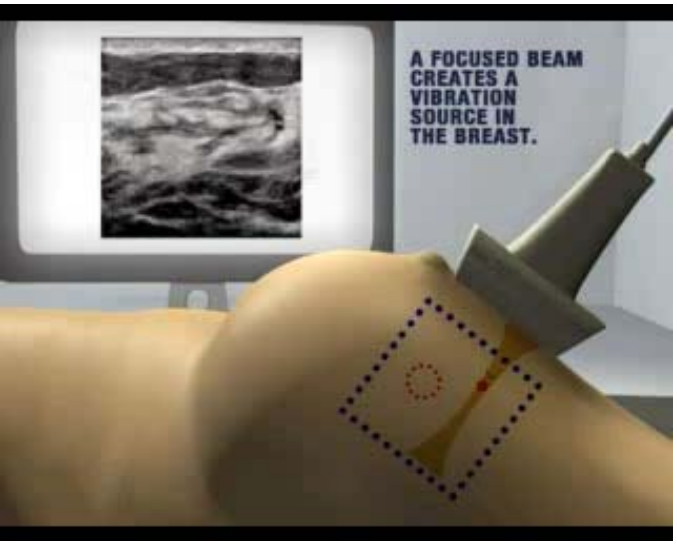

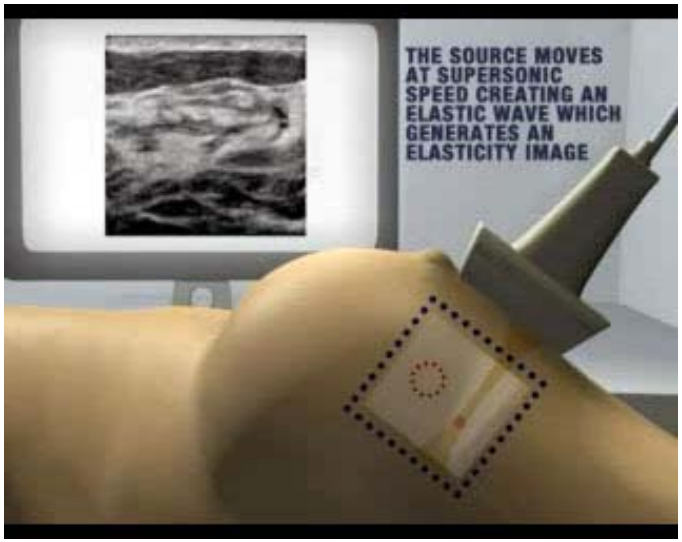

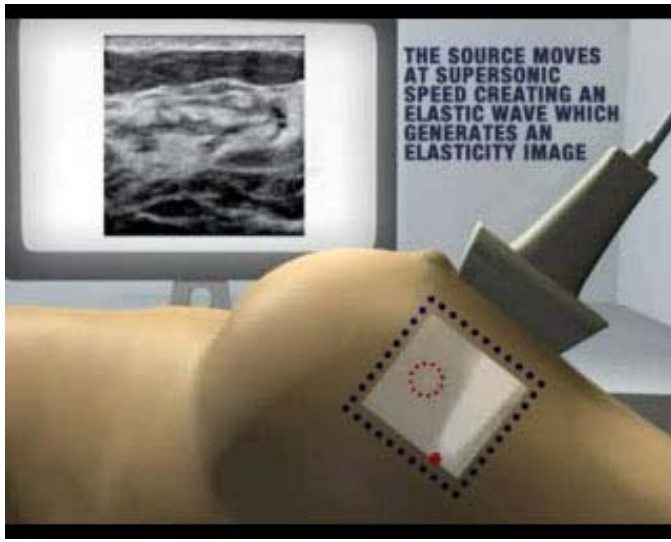

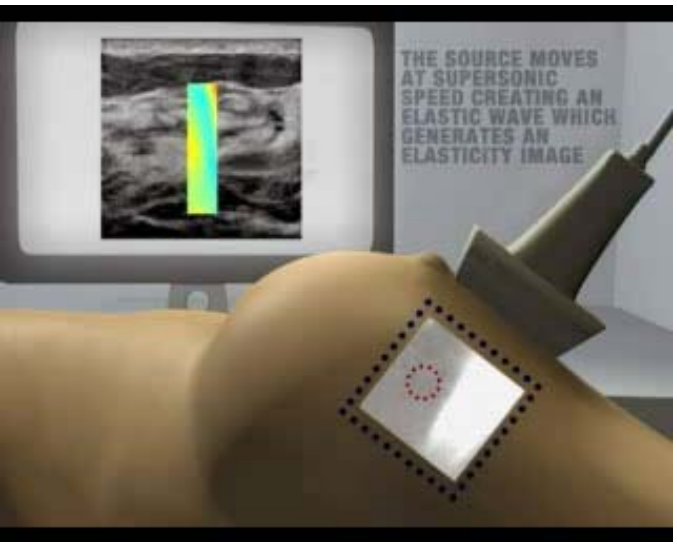

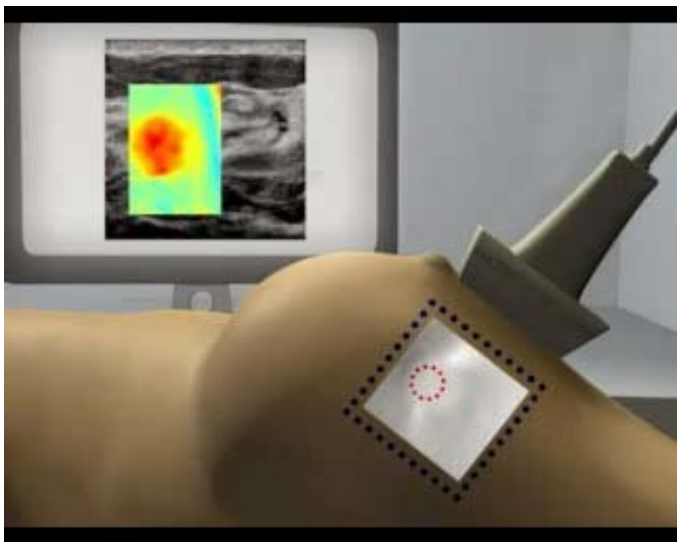

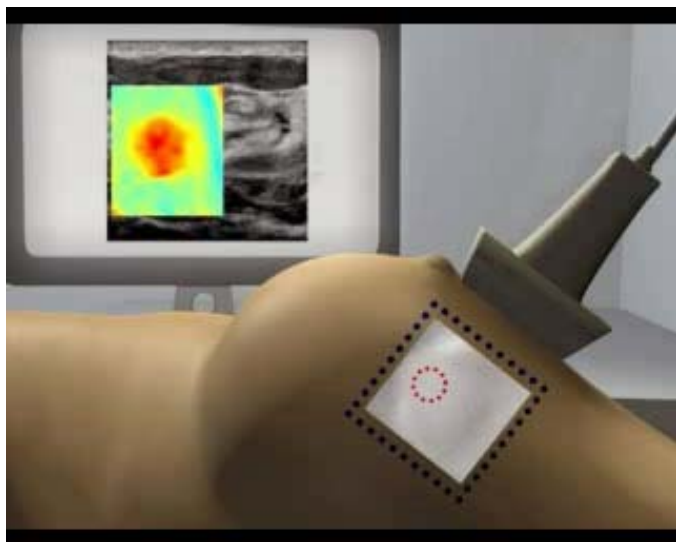

Liver:
Showing shear speed dispersion due to viscosity

Muller M et al. UMB;35:219, 2009

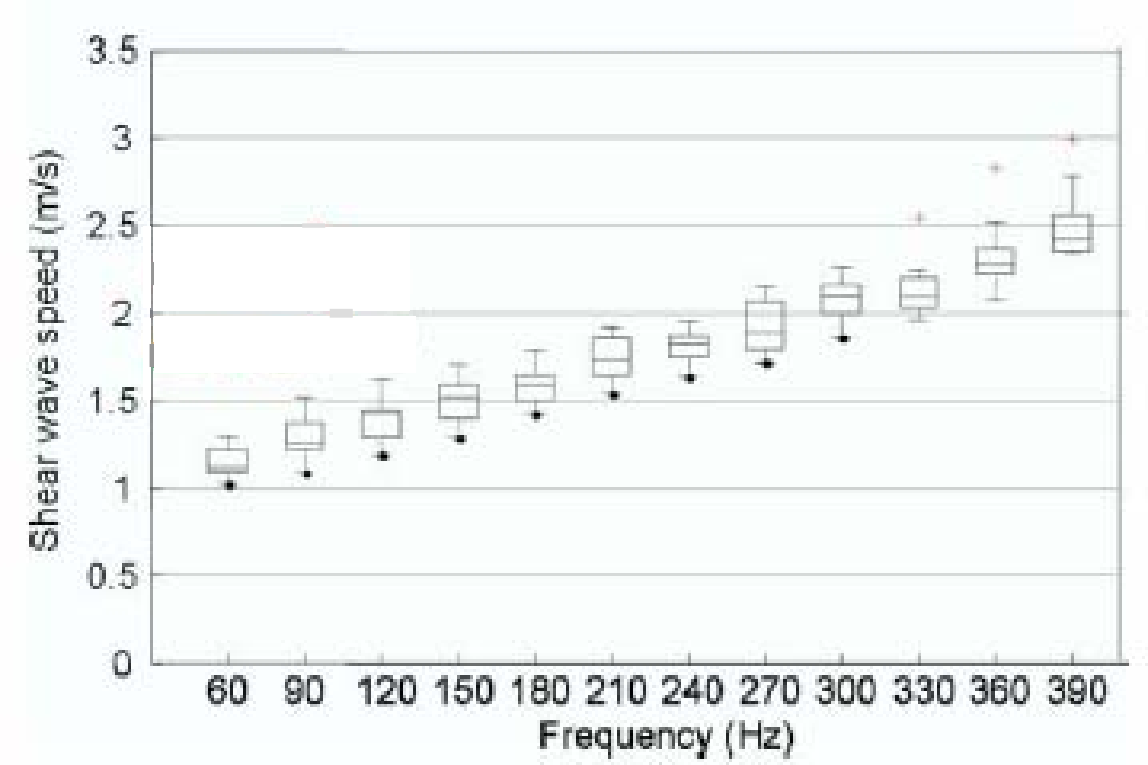

Other elasticity parameters under study

Tissue porosity and permeability

- Soft tissues contain free fluid in the interstitium and microvasculature, which flows when the tissue is compressed ➔
  - soft tissue is poroelastic (e.g. brain, cartilage, malignant tumours, oedematous tissues)
- Disease changes fluid properties in tissue (oedema, hydrocephalus, cancer)
- Permeability is important for drug access to cells
- Use of poroelastic theory to interpret strain images obtained using elastographic techniques:
  - New information
  - Prevent misinterpretations caused by applying traditional linear elastic assumptions

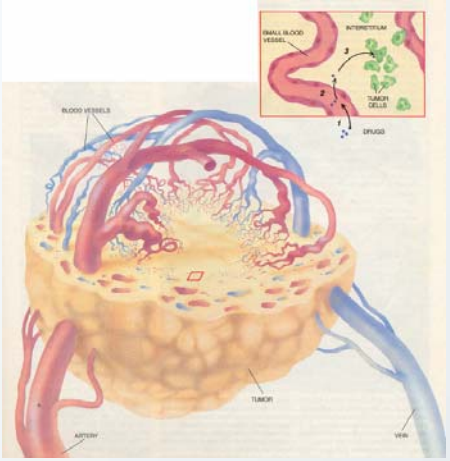

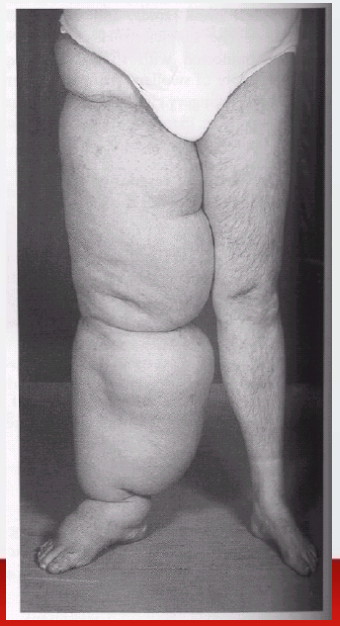

Poro-elastic Materials

- Two-phase poroelastic material:
  - solid phase or “matrix” (porous, permeable, elastic)
  - liquid phase (incompressible)

For example:

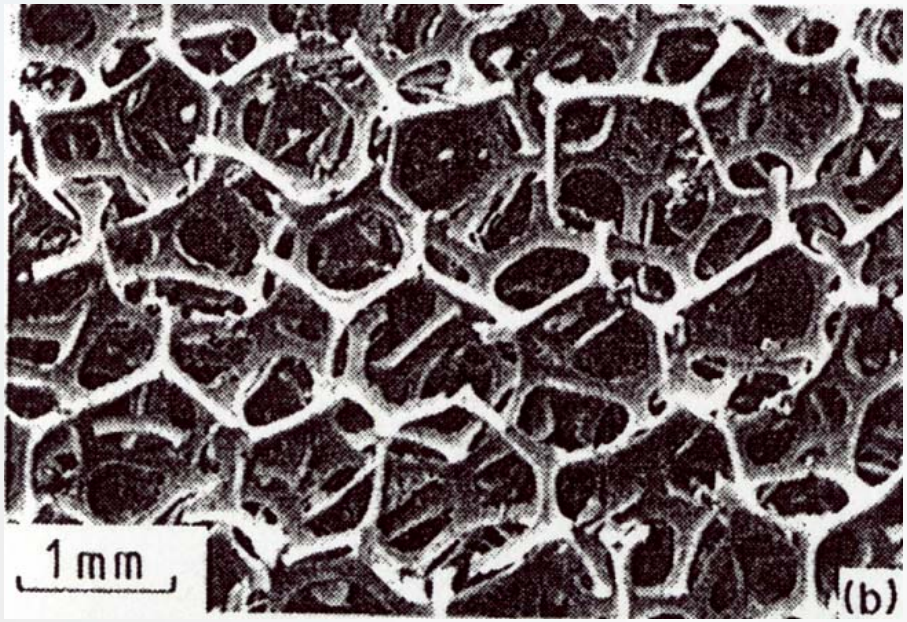

Adapted from

Gibson & Ashby (2002)

Relevance to Elastography

- When compressed, the solid matrix deforms and the pore fluid flows. Mechanical behaviour described by Biot (1941):

$$\nabla^2 \varepsilon = \frac{1}{H_A k} \frac{\partial \varepsilon}{\partial t}$$

where ε = volumetric strain

H_A = aggregate elastic modulus

k = permeability

t = time

$$H_A = \frac{E(1-\nu)}{(1+\nu)(1-2\nu)}$$

- Thus, compression-induced fluid flow causes a time-dependent spatially-varying strain similar to heat conduction

- Since strain is directly affected by fluid flow:
  - Fluid flow could influence elastograms
  - Strain imaging could be used to detect compression-induced fluid flow.

Elastography of a porous cylinder

Soya-bean gel (tofu)

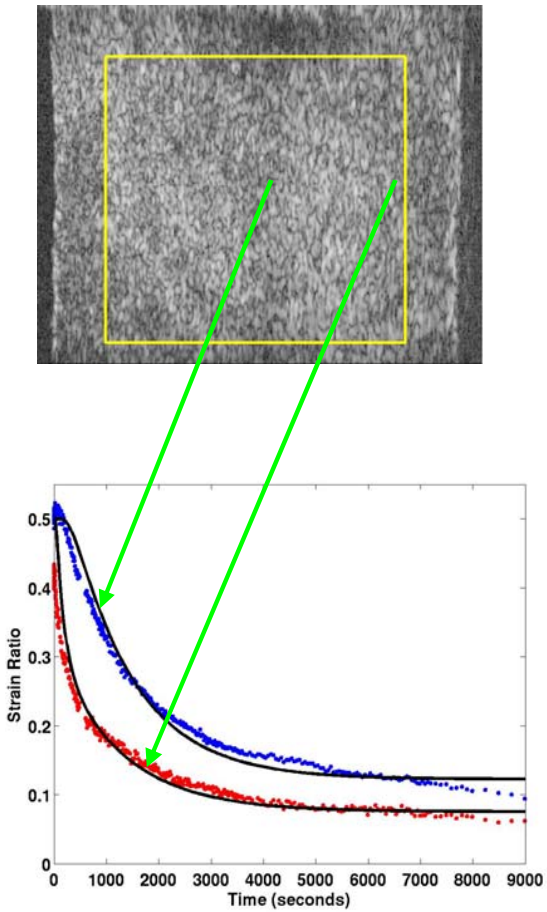

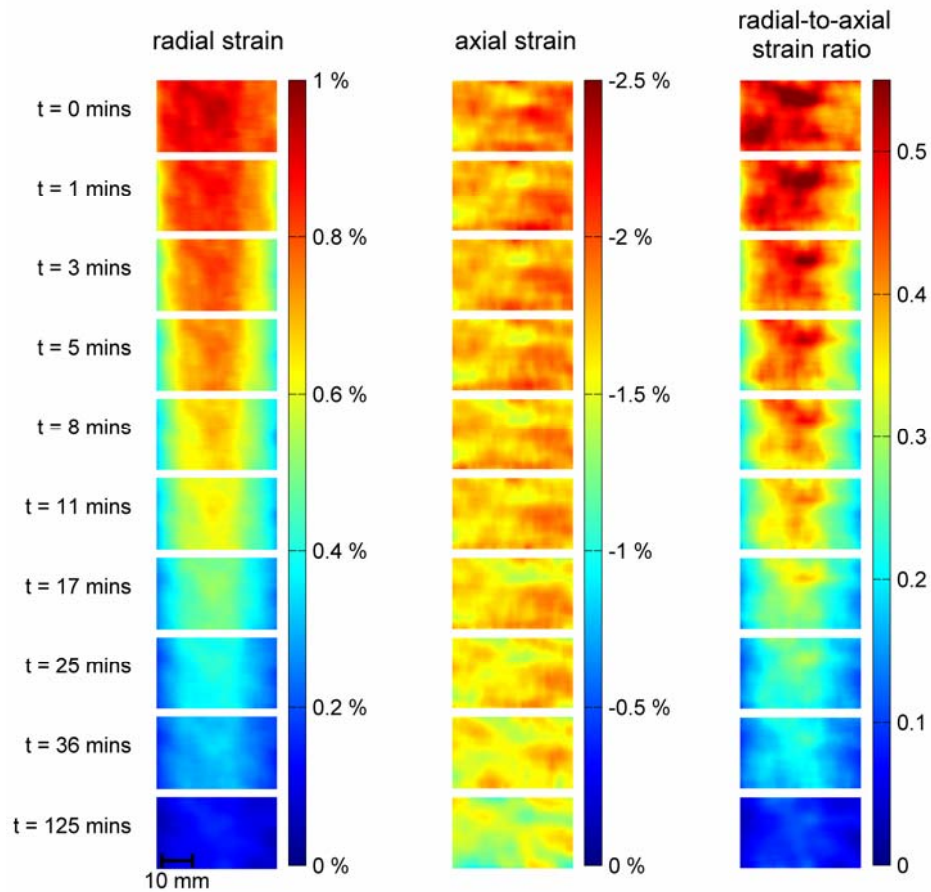

- Elastographic techniques can be used to image the slow fluid flow that is due to a sustained compression – including the direction of flow
- Imaging of quantities related to modulus, permeability and Poisson's ratio by fitting to the spatio-temporal dependence of volumetric strain

Berry GP et al (2006) Ultrasound Med Biol; 32:1869-1885.

Parametric Images for porous media

Product of Young's modulus and permeability

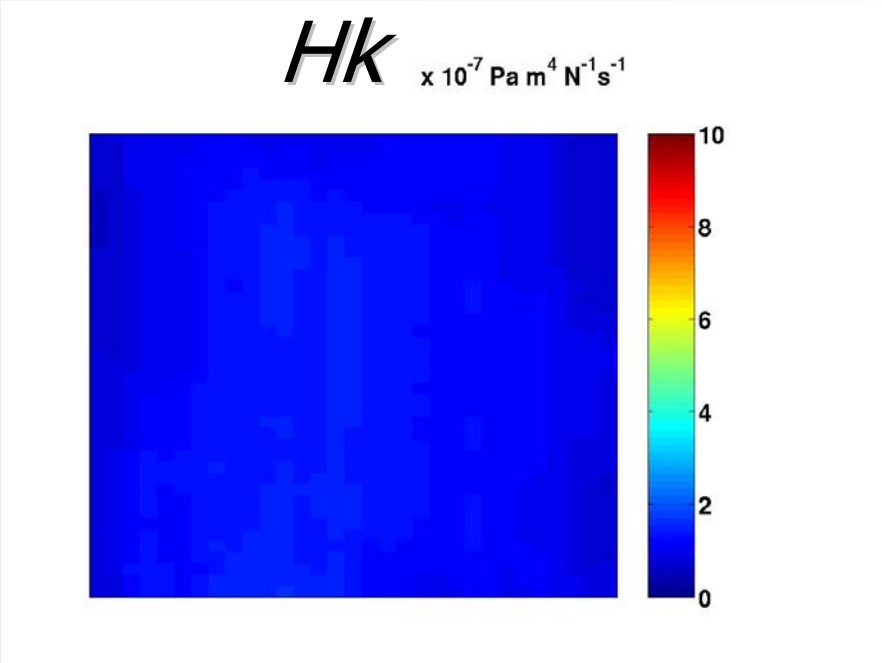

$1.15(\pm 0.21) \times 10^{-7}\ m^2 s^{-1}$

Poisson's ratio

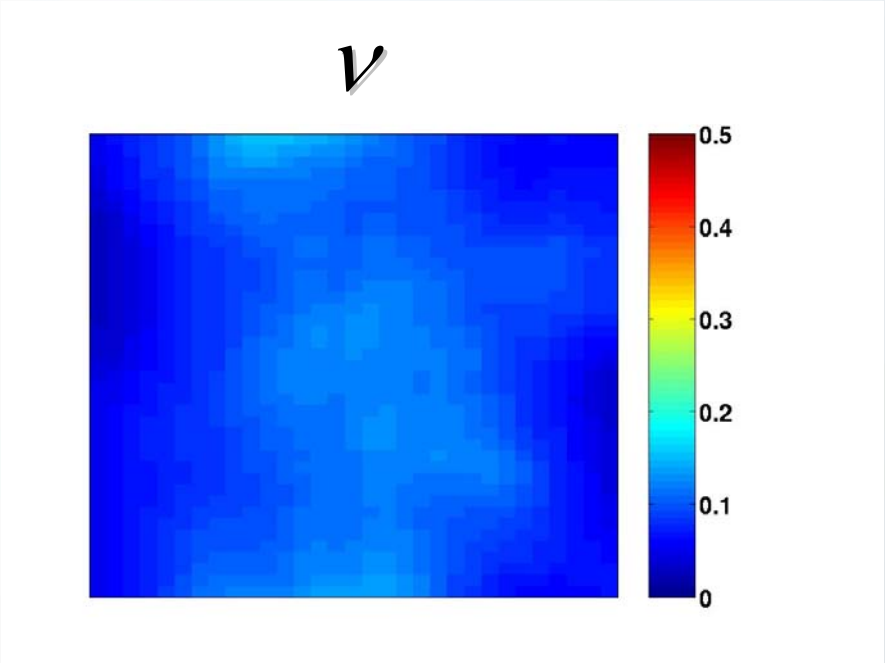

$0.095(\pm 0.0251)$

Berry GP et al (2006) Ultrasound Med Biol; 32:1869-1885.

Lymphoedema Trial

B-mode



'traditional' elastography



end-of-ramp

changes during sustained compression



50s 150s 275s 400s

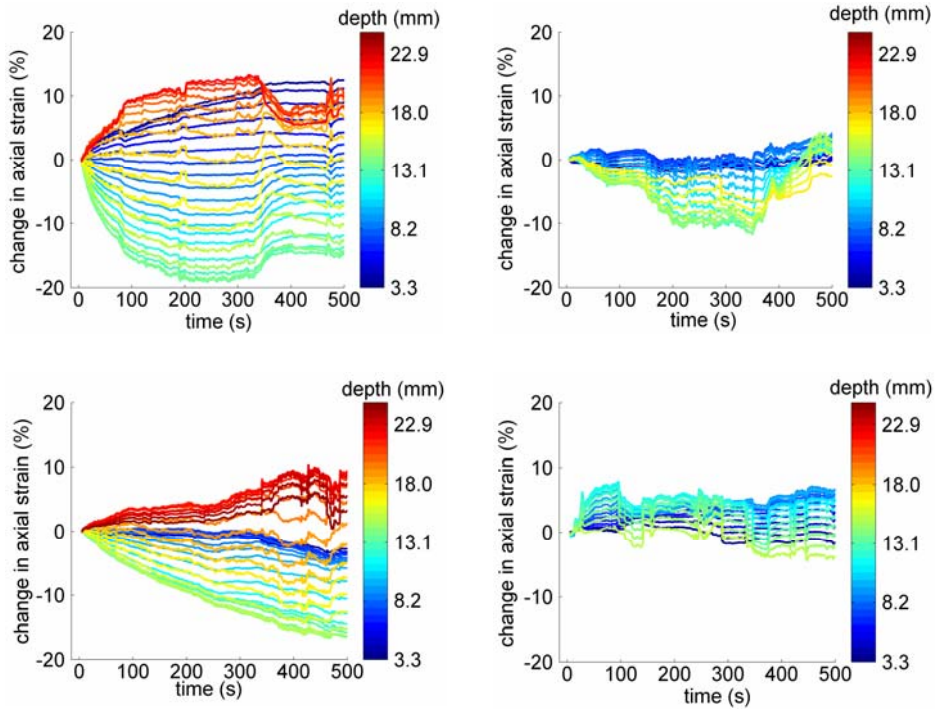

case 1

case 2

affected arm contralateral arm

Berry G et al Ultrasound Med Biol;34:617-629, 2008

Need for volumetric strain - example

(terri@terrifischer.com)

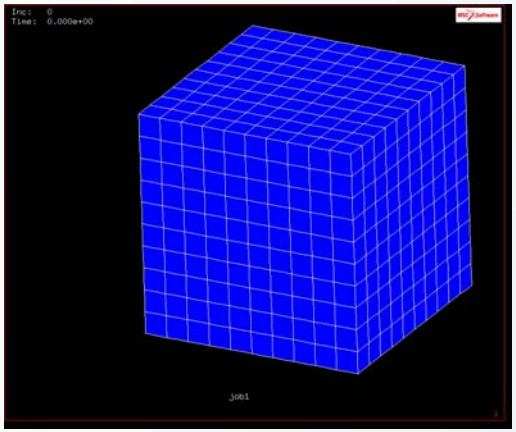

Finite element model

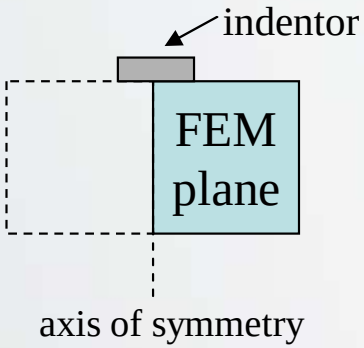

Axial strain (first 7 s)

Volumetric strain (first 7 s)

Modelling inhomogeneous and multi-compartmental poroelastic tissue

- Generalised theory to included a vascular compartment, and allow fluid exchange between the interstitium and the local microvasculature, i.e. now have E_s, ν_s , k and χ (microvascular filtration coefficient)

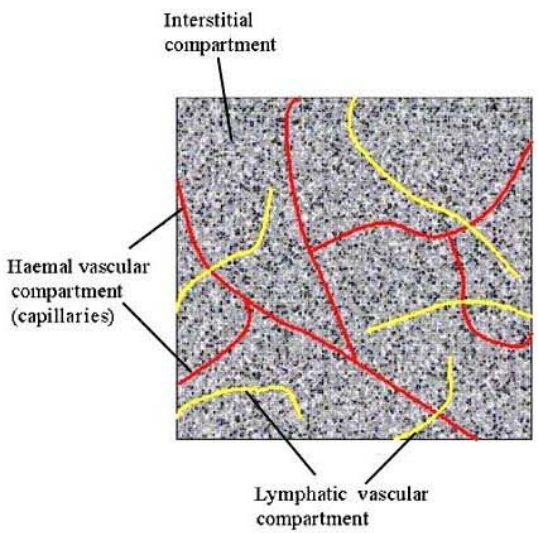

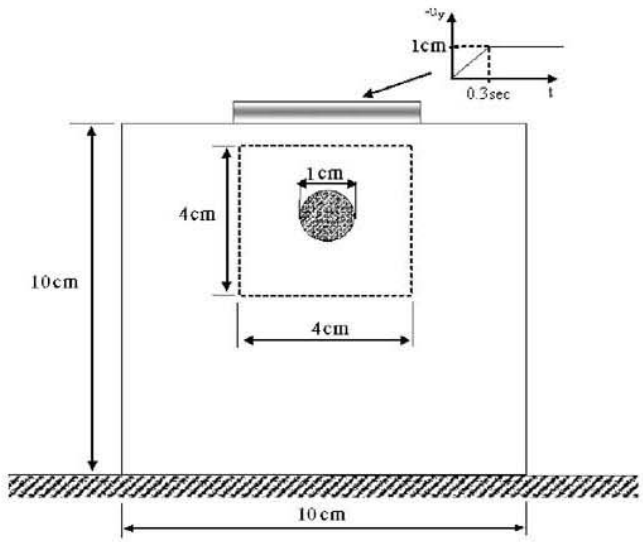

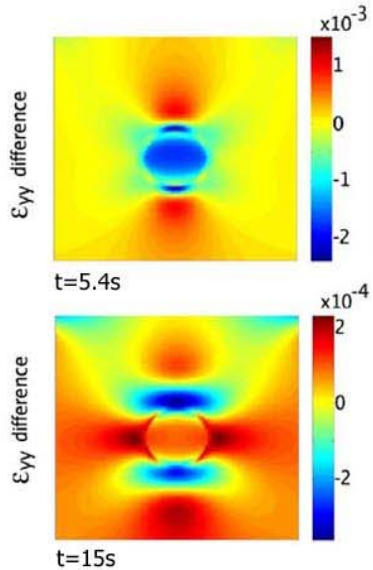

- Inclusion of simulated tumours - higher than normal values of E_s , k and χ (from the high density and leaky walls of microvessels associated with angiogenesis).

- Results suggest: (a) fluid drainage into local microvasculature should be the dominant flow-related stress/strain relaxation mechanism, (b) strain relaxation should be on the order of 5–10 s, (c) should be measurable by elastography.

Leiderman R. et al Phys Med Biol; 51:6291-6313 2006

Surface tensile strain for skin and subcutis



RF data acquisition

Computer for processing

Tensile Strain Images

Echo Image:

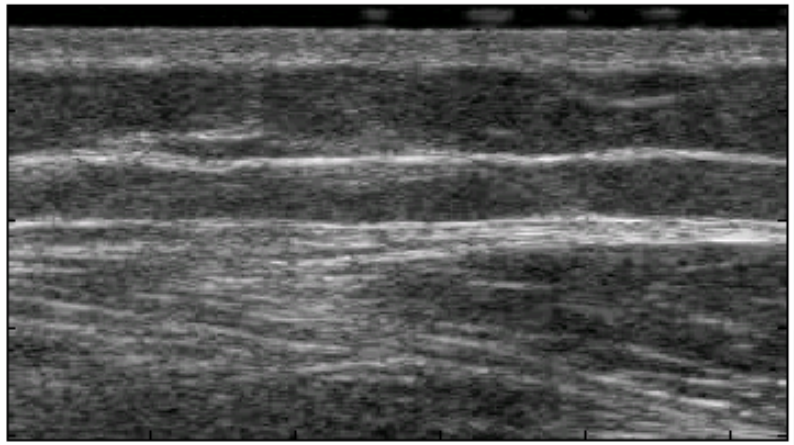

5mm



$\frac{du_x}{dx}$

Strain propagates through to the fat layer

Slip boundary properties may be used for diagnosis

$\frac{du_x}{dy}$

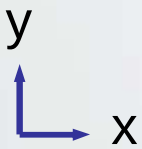

Coutts L (2006) Ultrasound; 14(3):161-166.

Anisotropy (in normal skin)

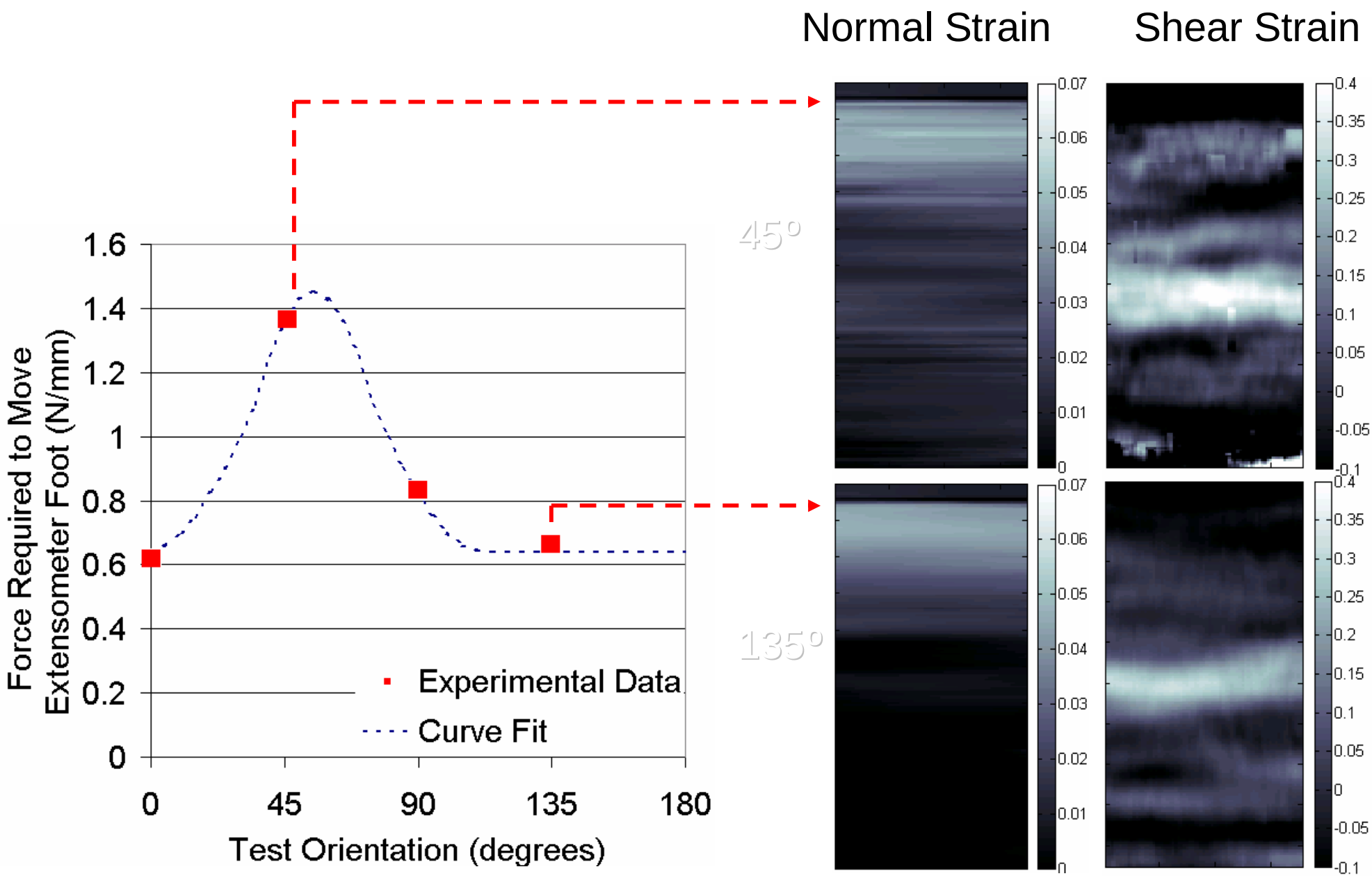

Coutts L (2006) Ultrasound; 14(3):161-166.

Conclusion

- Considerable opportunity to extract new and quantitative information on tissue characteristics – promising opportunities for inverse problem solving
- Ongoing work - 3D measurement of displacement/strain for quantification of mechanical properties

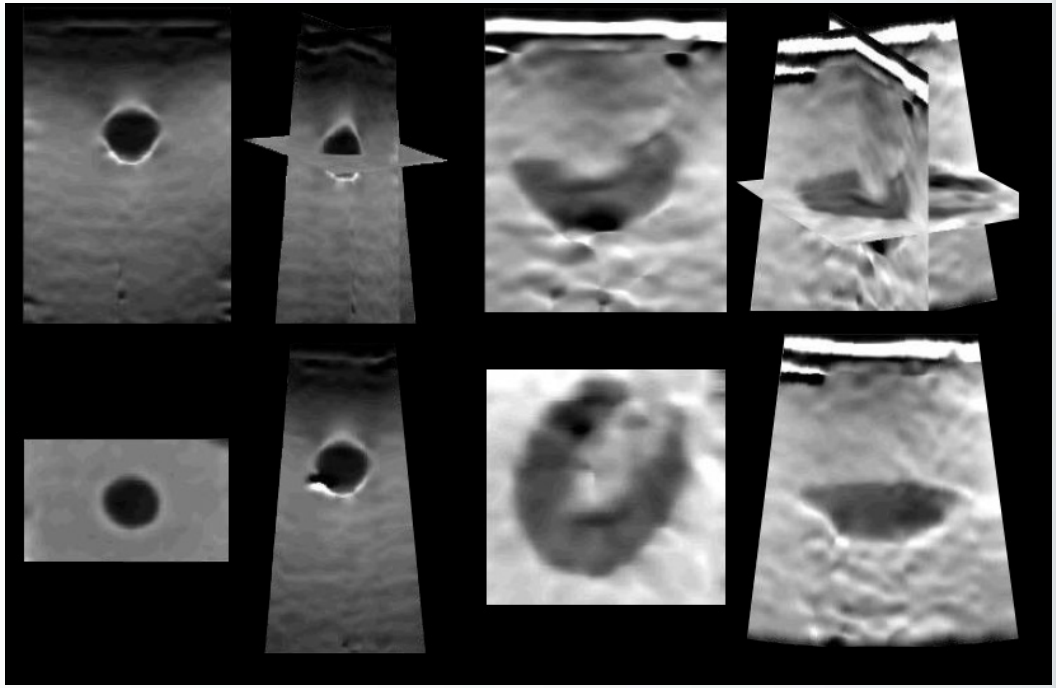

Gelatine phantom "Half-olive" phantom

Images courtesy of J. Lindop, G.Treece and A.Gee, University of Cambridge